

Aortic Dysphagia and Aortoesophageal Fistula: An Aggressive Evolution of an Uncomplicated Aneurysm of Descending Aorta or a Fatal Delay in Surgical Treatment?

Humberto Morais*

Department of Cardiology, Hospital Militar Principal/Instituto Superior, Luanda, Angola

Article Info

***Corresponding author:**

Humberto Morais

Department of Cardiology
Hospital Militar Principal/Instituto Superior
Rua Pedro Miranda 40.42. Maianga
República de Angola
E-mail: hmorais1@gmail.com

Received: August 4, 2017

Accepted: September 5, 2017

Published: September 12, 2017

Citation: Morais H. Aortic Dysphagia and Aortoesophageal Fistula: An Aggressive Evolution of an Uncomplicated Aneurysm of Descending Aorta or a Fatal Delay in Surgical Treatment?. *Madridge J Cardiol.* 2017; 2(1): 25-26.
doi: 10.18689/mjc-1000107

Copyright: © 2017 The Author(s). This work is licensed under a Creative Commons Attribution 4.0 International License, which permits unrestricted use, distribution, and reproduction in any medium, provided the original work is properly cited.

Published by Madridge Publishers

Abstract

We describe a case of a 65-year-old patient who developed a rare fatal complication of a previously asymptomatic descending aortic aneurysm over a two-week period. The authors emphasize the importance of complying with guidelines for the diagnosis and management of patients with thoracic aortic disease.

Keywords: Aneurysm; Descending aorta; Computed tomography; Acute aortic syndrome.

Case Report

A 62-year-old man was admitted at our hospital with chest pain, breathlessness and dysphagia for solids and liquids during two weeks. He had a past medical history of hypertension and a previous admission at our hospital a month ago, when a diagnosis of aneurysm of descending thoracic aorta was done (figure 1A). At that time, the thoraco-abdominal computed tomography revealed an aneurysm of descending thoracic aorta that measured 60x60 mm in the greatest dimensions on the axial view. The patient under anti hypertensive therapy became asymptomatic and he was discharged under anti-hypertensive therapy. A closed follow-up by internal medicine and angiology, according to the decision of the attending physicians was recommended. Two weeks later, the patient restart with chest pain, breathlessness and dysphagia for solids and liquids during two weeks. At admission, the blood pressure was at 130/80 mmHg. The chest X-ray showed extensive radiopacity in the left hemithorax suggesting an increase of the aneurysm size (figure 1B) when compared with previously one (figure 1A). Electrocardiography showed sinus rhythm. Contrast enhanced thoraco-abdominal computed tomography revealed an aneurysm of descending thoracic aorta that measured 72 x107 mm in the greatest dimensions on the axial view, an intramural hematoma and a penetrated aortic ulcer was also observed. The aneurysm compressed the esophagus, and the left bronchium (figure 2). The patient was referred for surgery. Twelve hours before the scheduled surgery, the patient had an episode of hematemesis and underwent emergency surgery. The patient died of uncontrolled hematemesis, an aortoesophageal fistula was found during surgery.

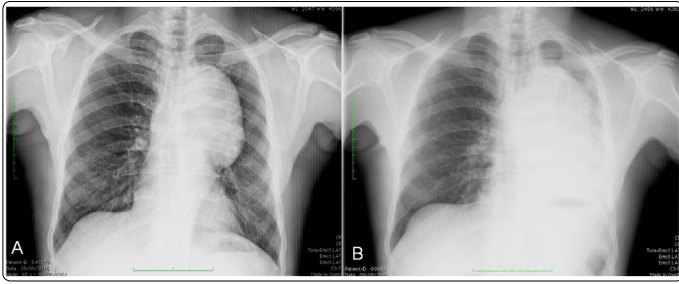


Figure 1. Chest x-ray showing: A - Enlargement of the mediastinum suggestive of a descending aortic aneurysm. B – Extensive radiopacity in the left hemithorax suggesting dramatic increase in aneurysm size.

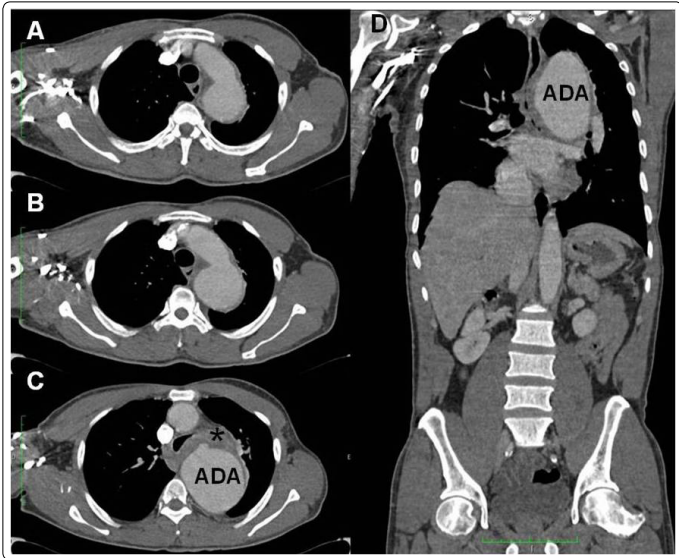


Figure 2. Contrast enhanced thoracic tomography - maximal intensity projection. Axial view (ABC) - showing aortic descending aneurysm with an intramural hematoma (C asterisk) and a penetrating ulcer of the aorta (C). Coronal view (D) - showing compression of the esophagus by the aneurysm. ADA - Aortic descending aneurysm.

Comments:

Aneurysm of the descending thoracic and thoracoabdominal aorta is a life-threatening disorder given the risks of aortic dissection or rupture and their associated high mortality and morbidity once complications occur. The decision to intervene prophylactically, however, is complicated by the significant mortality and morbidity associated with surgical intervention for these conditions. Current practice guidelines call for surgical repair of asymptomatic thoracic aortic aneurysms with diameters of ≥ 55 mm as a Class I recommendation [1]. Extensive thoracoabdominal aorta aneurysms are given a higher threshold of 60 mm [1].

The case described herein highlights a typical development of acute aortic syndrome in a patient with uncomplicated descending aortic aneurysm (60x60 mm) who became symptomatic and in whom the size of the aneurysm increased dramatically from 60x60 mm to 72x1.7 mm, and an intramural hematoma, a penetrating ulcer of the aorta followed by an aortic-esophageal ulcer with fatal hematemesis were developed over a period of two weeks. The rapid increase in aneurysm size is indicative of severe complications and should be an indication of immediate surgery, which was done in the case presented.

In conclusion, this case support the recommendation that patients with thoracic aortic aneurysms with diameters of ≥ 55 mm should be prompt referred for surgery even asymptomatic [2]. According to some authors [2] consideration might be given to lowering the threshold for intervention (>50 mm), particularly if less invasive endovascular approaches are feasible.

References

1. Hiratzka LF, Bakris GL, Beckman JA, et al. 2010 ACCF/AHA/AATS/ ACR/ ASA/SCA/SCAI/SIR/STS/SVM guidelines for the diagnosis and management of patients with thoracic aortic disease: a report of the American College of Cardiology Foundation/American Heart Association Task Force on Practice Guidelines, American Association for Thoracic Surgery, American College of Radiology, American Stroke Association, Society of Cardiovascular Anesthesiologists, Society for Cardiovascular Angiography and Interventions, Society of Interventional Radiology, Society of Thoracic Surgeons, and Society for Vascular Medicine. *J Am Coll Cardiol.* 2010; 55: e27–e129. doi: 10.1016/j.jacc.2010.02.015
2. Kim JB, Kim K, Lindsay ME, et al. Risk of rupture or dissection in descending thoracic aortic aneurysm. *Circulation.* 2015; 132(17): 1620-9. doi: 10.1161/CIRCULATIONAHA.114.015177