

Case Report

Open Access

## Granulomatous Mycosis Fungoides Presented as Multiple Subcutaneous Masses: a case of 5-year follow-up and Review of the Literature

Yin Fang<sup>1</sup>, Xu Xiao-Yun<sup>2</sup>, Chen Jia<sup>3</sup>, Song Ning-Jing<sup>1\*</sup> and Cheng Xing-Wang<sup>4\*</sup>

<sup>1</sup>Department of Dermatology, Tongren Hospital Shanghai Jiao Tong University School of Medicine, Shanghai, P.R. China

<sup>2</sup>Department of Dermatology, Jiangsu Province Geriatric Hospital, Nanjing, P.R. China

<sup>3</sup>Department of Dermatopathology, Shanghai Skin Diseases Hospital, Shanghai, P.R. China

<sup>4</sup>Department of General surgery, The Shibe hospital of Jingan district, Shanghai, P.R. China

### Article Info

#### \*Corresponding authors:

#### Song Ning-Jing

Tongren Hospital  
Shanghai Jiao Tong University School of  
Medicine  
Shanghai  
P.R.China  
E-mail: songnj-10@163.com

#### Cheng Xing-Wang

The Shibe hospital  
Jingan district  
Shanghai  
P.R.China  
E-mail: chengxingwangbb@163.com

**Received:** December 25, 2017

**Accepted:** January 29, 2018

**Published:** February 05, 2018

**Citation:** Fang Y, Xiao-Yun X, Jia C, Ning-Jing S, Xing-Wang C. Granulomatous Mycosis Fungoides Presented as Multiple Subcutaneous Masses: a case of 5-year follow-up and Review of the Literature. *Madridge J Cancer Stud Res.* 2018; 2(1): 34-39. doi: 10.18689/mjcsr-1000104

**Copyright:** © 2018 The Author(s). This work is licensed under a Creative Commons Attribution 4.0 International License, which permits unrestricted use, distribution, and reproduction in any medium, provided the original work is properly cited.

Published by Madridge Publishers

### Summary

Diagnosis of granulomatous mycosis fungoides is very challenging due to its clinical and pathological heterogeneity. We report a case of a 72-year-old female presented with 2 years scaly plaques, 5 months subcutaneous tumours on the sternum and left upper and both side lower extremities.

**Keywords:** Granulomatous Mycosis Fungoides; Histology; Treatment

### Introduction

Granulomatous mycosis fungoides (GMF) is a rare histological variant of cutaneous T-cell lymphoma (CTCL) [1], which was first described by Ackerman and Flaxman in 1970 [1]. GMF usually presented with non-specific skin lesions such as papule, macule, plaque, desquamation asymptomatic nodule, ulcer or tumor. However, the case of ichthyosiform eruption and subcutaneous mass has been reported rarely. We summarize a case of GMF a 72-year-old female initially presented with scaly plaques and subcutaneous tumors, which progressed to a tumoral cutaneous stage with sternum, anterior abdominal and axillary lymph nodes involvement.

### Report

A 72-year-old woman was referred to our clinic center in August 2012 presented with 2 years scaly plaques, 5 months subcutaneous masses on the sternum and left upper and both side lower extremities. The patient noticed scaly plaques with mild itching on the right lower limb in April 2010. She was hospitalized twice due to ichthyosis in April and June 2010. Ultrasound revealed enlarged lymph nodes in the subclavian, armpit, and groin. Infiltrative plaques appeared on the surface of her right thigh with no obvious symptoms initially, and sooner, similar symptoms and lumps successively emerged on the sternum and left upper and both side lower extremities but no burst. Six months later she was re-admitted. Biopsies showed granuloma formation in the dermis and subcutaneous tissue, with less heteromorphic cells and more giant cells. Immunohistochemical staining revealed that the tumor cells expressed CD3, CD45RO, but they were negative in L26, CD79a, Bcl-2. Some of atypical cells were CD4<sup>+</sup> and CD8<sup>+</sup>. T-cell receptor (TCR) gene analysis showed negative expression. Combining morphology and immunohistochemical staining with cloned gene rearrangement detection results, there was no certain malignant evidence. However, the rash still had no clear improvement

and the tumor continued to grow, so she came to our clinic to seek further medical treatment. Further questions about the disease revealed a subcutaneous mass history in her left pinkie without symptoms in September 2008 and then spread to her left ring finger. Histopathological recorded as chronic granuloma formation in local hospital and her two fingers were amputated in October 2009.

## Clinical Findings

Infiltrative dark erythematous plaques and desquamation presented in most surface skin in cutaneous examination. Subcutaneous tumors were found on the sternum, left upper and both side lower extremities (Fig.1 a,b,c) measuring from 2-3 cm to 6-7cm. Left little and ring finger were amputated (Fig.1d).

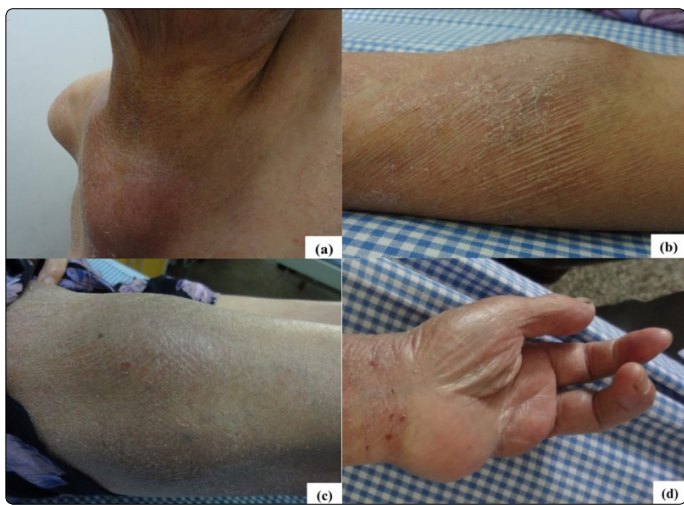


Figure 1. Subcutaneous tumour: (a) sternum; (b) left upper; (c) right lower limb. (d) Left little and ring finger were amputated.

## Ultrasound Examination

Subcutaneous masses appear in both ears, thighs and right anterior chest wall. Lymph node enlargement, especially in the neck and both groin.

## Computed Tomography Scan

The CT scans of the thorax, abdomen and pelvis demonstrated extensive involvements of sternum, anterior abdominal and axillary lymphadenopathy.

## Histology and Immunohistology

Histologically, the right thigh tumor showed that the dermis and hypodermis were massively and multifocal infiltrated by large multinucleated giant cells accompanied by inflammatory cells such as lymphocytes, histocytes and plasma cells (Fig.2). The neoplastic cells displayed an immunophenotype of CD3<sup>+</sup>, CD4<sup>+</sup>, CD5<sup>+</sup>, CD45RO<sup>+</sup>, CD68<sup>+</sup>, S-100<sup>+</sup>, Ki-67<sup>+</sup>, PCNA<sup>+</sup>, LCA<sup>-</sup>, CD8<sup>-</sup>, CD79a<sup>-</sup>, CD20<sup>-</sup>, CD30<sup>-</sup>, CD56<sup>-</sup>, CD1a<sup>-</sup> (Fig.2) pattern. Immunohistology of axillary lymph node revealed similar results to the right thigh tumor (Fig.2, Fig.3).

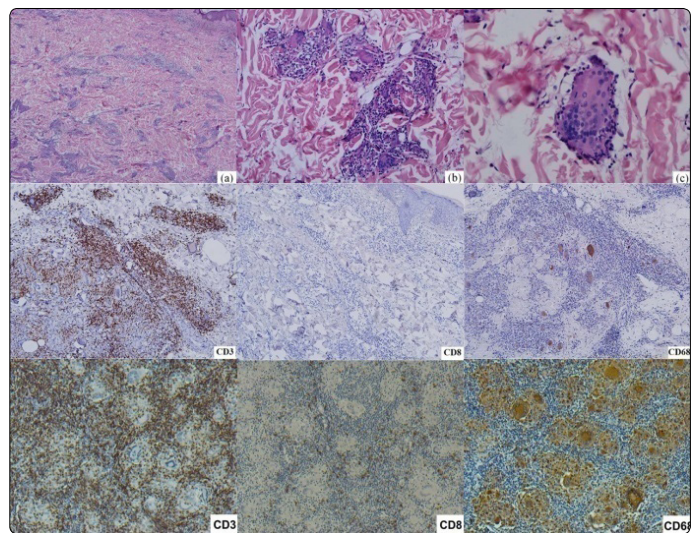


Figure 2. HE and Immunohistochemistry staining :The dermis and hypodermis were massively and multifocal infiltrated by large multinucleated giant cells accompanied by infiltrating inflammatory cells, (a) HE×40; (b) HE×100; (c) HE×400.(right thigh tumour).

Immunohistochemistry staining showing: CD3(+),×100; CD8(-),×100; CD68(+),×100.(right thigh tumour). CD3(+),×100; CD8(+),×100; CD68(+),×100.(axillary lymph nodes)

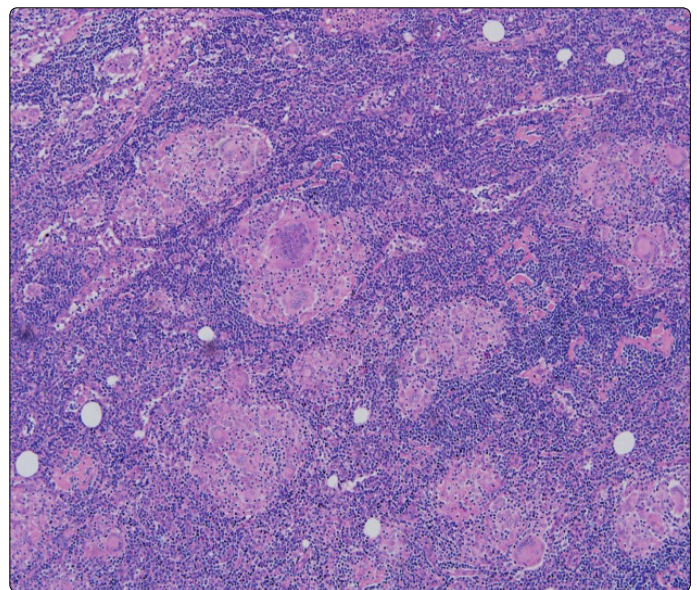


Figure 3. Lymph nodes were massively and multifocal infiltrated by large multinucleated giant cells accompanied by infiltrating inflammatory cells similar to the skin biopsies. HE×100. (axillary lymph nodes)

These results indicated that lymph nodes were also involved.

## TCR Gene Analysis

TCR gene analysis of the right thigh biopsy specimen displayed TCRB<sup>+</sup>, TCRD<sup>+</sup>, TCRG<sup>-</sup> (Fig.4), providing evidence of a T-cell monoclonal proliferation.

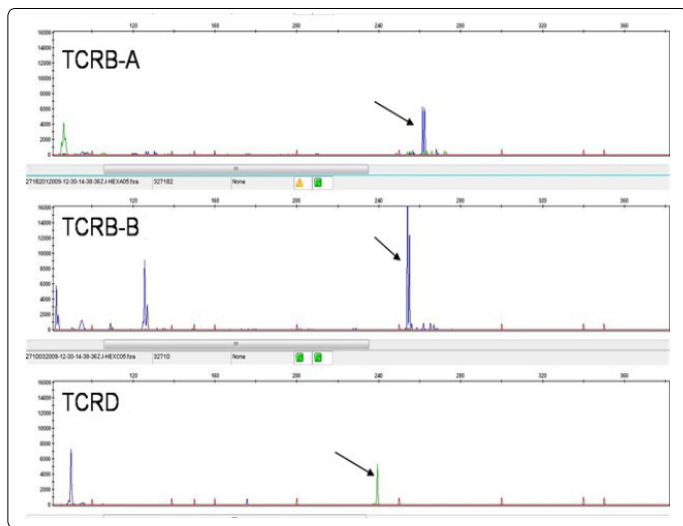


Figure 4. The result of TCR gene analysis: Monoclonal TCR-β (TCRB Tube -A□tube-B) and TCR-δ (TCRD Tube) gene rearrangements were detected; Monoclonal TCR-γ gene rearrangements were not detected (TCRG tube -A□tube-B).

### Diagnosis

With the combination of clinical presentation, histopathology, immune histology and TCR gene analysis, the diagnosis of granulomatous mycosis Fungoides (GMF) tumor-stage with lymph node involvement was made.

### Treatment and Prognosis

The patient was treated with prednisone 20mg and isotretinoin 20mg per day and moisturizer for external use. The masses were gradually disappeared one month after the treatments. The medication doses were tapered off due to the disease progression. Follow-up has been continuing.

### Discussing

Granulomatous mycosis fungoides was first described by Ackerman and Flaxman in 1970, who reported a patient with tumor-stage MF with giant cells dermal infiltration [1]. It is a rare histopathological type of mycosis Fungoides (MF) which exhibited characteristic expression of granulomatous reaction with the atypical lymphocytic infiltration [1]. The clinical manifestations of GMF were lack of specificity, therefore GMF cannot be simply diagnosed from the skin rash. It also needs additional tests, such as histopathology, immune histology and TCR gene analysis.

Since the first case of GMF in 1970, at least 41 cases have been reported in the literature. We summarized the clinicopathologic characteristics, prognosis, and therapeutic responses of GMF (Table 1).

Table 1. Literature review, Case data on clinical features, histological observations, therapy and survival of disease

NO./Ref.	Age /sex	Location	Lesion Type	Phenotype	TCR	Therapy	Survival (month)
NO.1/1	46/M	thighs abdomen	plaques, nodule, ulcerated	/	/	MTX	>384
NO.2/21	59/F	/	plaques, erythema	/	/	nitrogen mustard electron beam	>96
NO.3/22	47/M	/	plaques, ulceration, patches nodule	/	/	carmustine	>63
NO.4/23	52/M	/	plaques, ulcerating tumours	/	/	radiotherapy	25
NO.5/23	59/M	/	scaly erythema,	/	/	electron beam	480
NO.6/23	67/F	/	scaly, plaques, erythroderma	/	/	electron beam chlorambucil, prednisolone	45
NO.7/23	81/F	/	/	/	/	electron beam azarabine	264
NO.8/24	38/F	left forearm Abdomen left flank thigh knee	nodules, plaques, erythema	CD2+, CD3+, CD4+, CD5+, CD7+, CD45+, HLA-DR+, CD30-	TCR-	extracorporeal photopheresis	>142
NO.9/24	33/M	legs, calves, forearms, back	plaques, nodules	CD2+, CD4+, CD5+, CD7+, HLA-DR+, CD30-	TCR+	nitrogen mustard	>44
NO.10/25	31/F	/	plaques, ulceration, atrophic	CD2+, CD3+, CD4+, CD5+, CD7-	/	interferon-α	62
NO.11/14	39/F	thigh left flank	plaques nodules erythroderma	UCHL1+, CD2+, CD3+, CD4+, CD5+, CD30+, CD7-, CD19-, CD21-, CD37-	TCR+	electron beam PUVA	>355
NO.12/26	60/M	/	plaques/ulceration/tumours/	CD3+, CD4+, UCHL1+, CD30+, CD8-	TCR-	PUVA radiotherapy	>12
NO.13/27	39/M	/	plaques, nodules	CD2+, CD3+, CD5+, CD7+, CD4+, CD8-	TCR+	None	>87
NO.14/11	71/M	left groin face, thighs, trunk	plaques, papules, nodules	CD3+, CD4+; CD8-, CD22-, CD30-	TCR+	interferon-γ PUVA	48
NO.15/28	60/M	/	erythe-matous scaly plaques	HLA-DR II+, CD2+, CD3+, CD4+, CD5+, CD7+, CD8-	/	PUVA radiotherapy	>12

NO.16/29	34/M	trunk, scapular	erythematous plaques	/	/	PUVA radiotherapy chlormethine	/
NO.17/16	82/M		erythe-matous patches	CD3+,CD45Ro+, CD43+	TCR+	interferon-γ PUVA	>27
NO.18/17	52/M	face, neck, upper arms and legs	poikilodermatic healing tumours, plaques	/	TCR+	radiotherapy PUVA Interferon-α	149
NO.19/17	88/M	trunk head	ulceration/tumour/papules	CD3+	TCR+	radiotherapy	32
NO.20/30	68/M	trunk right neck left forearm groin	erythematous plaques tumour nodes	CD3+,CD45Ro+, CD43+, CD20-	/	systemic chemotherapy	23
NO.21/20	52/M	trunk, thighs	plaques nodules tumour	CD3+,CD43+, CD20-,CD79a-	TCR+	electron beam radiotherapy interferon photopheresis	16
NO.22/15	46/M	upper arm	poikilodermatic	CD4+,CD74+, CD45RO+, Bcl-2+, CD15-,CD20-CD30-	/	radiotherapy interferon-α	>27
NO.23/31	61/F	widespread	erythematous scaly patches/ plaques/ulcerated	CD3+,CD4+, CD45RO+, TIA-1+	TCR+	gemcitabine	>12
NO.24/32	69/M	forearms, legs, chest, back	ichthyosiform erythematous	CD4+,CD7-	TCR+	PUVA	>12
NO.25/33	40/F	chest	erythematous tumour ulceration	CD3+,CD4+, CD5+, CD45RO+, CD8+,CD30+	TCR+	radiotherapy oral prednisolone azathioprine	>60
NO.26/34	55/M	right thigh	tumor, nodules	/	/	/	/
NO.27/35	62/F	/	no skin lesions	/	/	steroid	/
NO.28/36	20/F	knees ankles elbows wrists	erythema	CD3+,CD4+ CD45RO+, CD8+,CD30-, CD56-,TIA-1-	TCR+	interferon, PUVA, radiation	>36
NO.29/37	41/M	chest	poikiloderma, ichthyosis and erythematous scaly plaque	/	TCR+	topical steroids PUVA	36
NO.30/38	75/F	trunk extremities	brownish maculae nodupoikilodermatousle-s	βF1+,CD3+,CD8+ TIA-1+; CD4-,CD20-CD56-	/	PUVA	>21
NO.31/39	38/M	Chest upper back	erythema poikilodermatous	LCA+,CD3+	/	chemotherapy	/
NO.32/40	42/M	trunk lower extremities	ulceration plaques	/	/	/	/
NO.33/41	69/F	Right axillary, scalp	erythema papules, plaque	βF1+,CD3+,CD4+ CD21+,CD8, CD20-,CD30-CD56-	TCR+	/	>72
NO.34/42	86/M	head, neck, and hip	tumors	CD4+,CD68+ CD7-	/	topical corticosteroid nb-uvb irradiation.	>65
NO.35/43	74/M	/	macules plaques	/	/	bexarotene PUVA	/
NO.36/44	29/F	extremities, flanks, buttocks, abdomen, axillary	depigmented macules patches erythematous nodules	/	/	phototherapy	/
NO.37/45	88/F	neckline	erythematous plaque telangiectasia	CD3+,CD4+, CD5+,CD8+, CD30-	/	topical steroids	lost to followup
Our case	72/F	sternum left upper extremities	scaly plaques, subcutaneous masses	CD3+,CD4+, CD5+,CD68+, CD45RO+,CD8-CD79a-,CD20-CD30-,CD56-CD1a-	TCR+	prednisone isotretinoin	>42

GMF usually presented as non-specific skin lesion such as papule, macule, plaque, desquamation asymptomatic nodule or tumor. Acquired ichthyosis is supposed to be one of the cutaneous manifestations of a variety of malignancies [2]. In recent years, certain GMF cases with an ichthyosi form eruptions have also been reported [3].

Histopathological characteristics of GMF showed the basis of the typical mycosis granuloma (MF) with different quantities of granulomas, with tumor cells and epithelioid cells in filtrating, accompanied by elastic fiber atrophy. Granulomas can be observed in a variety of cutaneous T cell lymphomas (CTCLs), including sezary syndrome, primary

cutaneous small/medium T cell lymphoma, primary cutaneous anaplastic large cell lymphoma, adult t-cell lymphoma, and primary cutaneous B-cell lymphomas [4-7]. However, GMF is the most common form of primary cutaneous malignant lymphoma showing granulomatous features [8]. About 2% of CTCLs cases express granuloma formation [9]. Characteristically, multinucleated giant cells showed emperipolesis of lymphocytes containing phagocytized elastic fibers. Lymphocytic epidermotropism is almost always common. Immunopheno typing of the majority of GMF cases manifest positive for CD3, CD4, CD5, CD45RO [10], while mostly negative for CD8, CD30 [11] versus extremely rare CD8-positive in GMF [12]. The analysis of T-cell clonality (TCR-PCR) is helpful for distinguishing granulomatous inflammatory reactions from granulomatous CTCLs, such as GMF.

GMF is easy to be misdiagnosed as inflammatory granuloma or infectious granulomas, such as granuloma annular (GA), sarcoidosis, and so on [13]. Histopathology, immunohistology and TCR gene analysis are helpful in differential diagnosis. A case of GMF presenting as sarcoidosis was reported in 1996 [14]. GMF and granulomatous slack skin (GSS) are both a lymphoma of T-cells, with similar histopathological and immune phenotype. GSS must be differentiated from GMF with the presence of marked epidermotropism, an extensive dermal infiltrate of granulomas, distinct elastophagocytosis and almost completely disappeared elastic fibers [8, 14-15]. However, it is still difficult to distinguish between the two diseases by histopathology, while the clinical presentation of GSS is very characteristic, with bulky pendulous axillar and inguinal skin folds [8]. Some scholars hold that GMF is the early stages of GSS and both of them belong to a spectrum of the same entity [16]. Various therapies have been applied to treat GMF including PUVA, glucocorticoid, interferon alpha, retinoids, systemic chemotherapy, radiation and chemotherapy [17-18]. In the current case, we treat the patient with oral prednisone and isotretinoin. The masses were mainly disappeared after one month of treatment. To consolidate the efficacy, isotretinoin had been continuously administered for the next 6 months, while prednisone was tapered off after the first month treatment. In May 2013 (2 months after the regimen), a few local skin ulcers appeared on the chest and right lower limb (Fig.5).

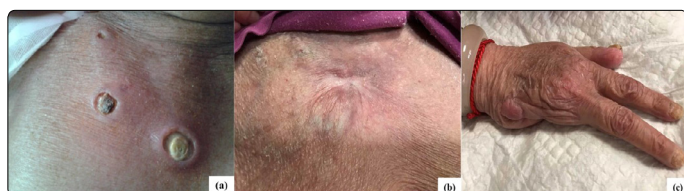

Figure 5. (a) ulcers on the chest; (b) the ulcers were slow to heal; (c) the amputated fingers

After a routine surgical treatment and hormone treatment, the ulcers slowly healed in one month. At present the patient was on prednisone (2.5 mg per day) as maintenance therapy. Patient has been free of tumorous symptoms for more than three years. Prednisone and isotretinoin regimen worked well

in this case and avoid spectrum of side effects caused by systemic chemotherapy, radiation and chemotherapy.

The prognosis and clinical significance of granulomatous reaction in MF is not yet clear. Traditionally, granulomatous are an immune mechanism of self-protection, which is helpful for tumor regression and disease remission, and an indicator of favorable prognosis [7, 19]. However, many scholars consider that some patients of CTCL with granulomatous reaction express speedy development, high invasive, poor prognosis, may indicate disease is in progress to those with a poor outcome [11, 20]. Previous study reported that the 5-year-survival of GMF was 66%, which was worse than classic MF [9]. Nearly 40% of GMF patients died for their disease, and 50% of them died within 5 years of the onset of rashes [12]. In our case, during 52 months follow-up, the skin lesion progressed slowly with no other systemic involvement (Fig.5).

In this case, patient presented with non-specific skin lesion, infiltrative dark erythematous plaques, desquamation, nodule and tumor. Combining clinical manifestations, histopathological examination with TCR gene rearrangement results, the diagnosis of GMF was confirmed. Before the appearance of the rash, there was a mass in her left pinkie without symptoms in September 2008 and it then spread to her left ring finger. Histopathological recorded chronic granuloma formation, which might be the early manifestation of GMF. Unfortunately, immunohistochemical and other further examinations were not taken at that time. The presence of granulomatous infiltrate in the early stage of GMF may result in a misdiagnosis. Identification in early stage is critical to prompt treatment and better prognosis, let alone that this patient presented with as rarely described ichthyosi form skin eruption in its early stage. It is worth noticing that clinical heterogeneity of GMF is very common. The pathogenesis, the relationship among them, influences on the progression and prognosis are worthwhile studying thoroughly. In the current case, we noted that merely small doses of oral prednisone also achieved good therapeutic effect. Therefore, whether small doses of oral prednisone would be a reliable long-term maintenance treatment therapy for GMF, or only a part of heterogeneity of GMF?

## Conflict of interest

The authors confirm that there is no conflict of interest regarding this manuscript.

## References

1. Ackerman AB, Flaxman BA. Granulomatous mycosis fungoides. *Br J Dermatol.* 1970; 82: 397-401.
2. Schwartz RA, Williams ML. Acquired ichthyosis: a marker for internal disease. *Am Fam Physician.* 1984; 29(2): 181-184.
3. Eisman S, O'Toole EA, Jones A, et al. Granulomatous mycosis fungoides presenting as an acquired ichthyosis. *Clin and Exp Dermatol.* 2003; 28(2): 174-176.
4. Carrozza PM, Kempf W, Kazakov DV, et al. A case of Sezary's syndrome associated with granulomatous lesions, myelodysplastic syndrome and transformation into CD30-positive large-cell pleomorphic lymphoma. *Br J Dermatol.* 2002; 147(3): 582-586.

5. Scarabello A, Leinweber B, Ardigo M, et al. Cutaneous lymphomas with prominent granulomatous reaction: a potential pitfall in the histopathologic diagnosis of cutaneous T- and B-cell lymphomas. *Am J Surg Pathol.* 2002; 26(10): 1259-1268.
6. Li SM. Anaplastic large cell lymphoma associated with tuberculoid granulomatous reaction: report of a case. *Zhonghua Bing Li Xue Za Zhi.* 2006; 35(2): 124-125.
7. Higaki Y, Mizushima J, Kawashima M, et al. Cutaneous granulomas associated with adult T-cell leukemia/lymphoma. *Dermatology.* 2003; 206(2): 157-160. doi: 10.1159/000068460
8. Kempf W, Ostheeren-Michaelis S, Paulli M, et al. Granulomatous mycosis fungoides and granulomatous slack skin: a multicenter study of the Cutaneous Lymphoma Histopathology Task Force Group of the European Organization for Research and Treatment of Cancer (EORTC). *Arch Dermatol.* 2008; 144(12):1609-1617. doi: 10.1001/archdermatol.2008.46
9. Shapiro PE, Pinto FJ. The histologic spectrum of mycosis fungoides/Se'zary syndrome (cutaneous T-cell lymphoma): a review of 222 biopsies, including newly described patterns and the earliest pathologic changes. *Am J Surg Pathol.* 1994; 18(7): 645-667.
10. Fung MA, Murphy MJ, Hoss DM, et al. Practical evaluation and management of cutaneous lymphoma. *J Am Acad Dermatol.* 2002; 46: 325-357.
11. Chen KR, Tanaka M, Miyakawa S. Granulomatous mycosis fungoides with small intestinal involvement and a fatal outcome. *Br J of Dermatol.* 1998; 138(3): 522-525.
12. Ishida M, Hotta M, Takikita-Suzuki M, et al. CD8-positive granulomatous mycosis fungoides: a case report with review of the literature. *J Cutan Pathol.* 2010; 37(10): 1072-1076. doi: 10.1111/j.1600-0560.2010.01577.x
13. Pfaltz K, Kerl K, Palmado G, et al. Clonality in Sarcoidosis, Granuloma Annulare, and Granulomatous Mycosis Fungoides. *Am J Dermatopathol.* 2011; 33(7): 659-662. doi: 10.1097/DAD.0b013e318222f906
14. Bessis D, Sotto A, Farcet JP, et al. Granulomatous Mycosis Fungoides Presenting as Sarcoidosis. *Dermatology.* 1996; 193(4): 330-332.
15. Wollina U, Graefe T, Fuller J. Granulomatous slack skin or granulomatous mycosis fungoides: a case report complete response to percutaneous radiation and interferon alpha. *J Cancer Res Clin Oncol.* 2002; 128(1): 50-54.
16. Metzler G, Schlagenhauß B, Kröber SM, et al. Granulomatous mycosis fungoides: report of a case with some histopathologic features of granulomatous slack skin. *Am J Dermatopathol.* 1999; 21(2): 156-160.
17. Fischer M, Wohrlab J, Audring TH, et al. Granulomatous mycosis fungoides. Report of two cases and review of the literature. *J Eur Acad Dermatol Venereol.* 2000; 14(3): 196-202. doi: 10.1046/j.1468-3083.2000.00047.x
18. Zackheim HS. Cutaneous T cell lymphoma: update of treatment. *Dermatology.* 1999; 199(2): 102-105. doi: 10.1159/000018214
19. Dabski K, Winkelmann RK. Generalized granuloma annulare: clinical and laboratory findings in 100 patients. *J Am Acad Dermatol.* 1989; 20(1): 39-47.
20. Gomez-De La Fuente E, Ortiz PL, Vanaclocha F, et al. Aggressive granulomatous mycosis fungoides with clinical pulmonary and thyroid involvement. *Br J Dermatol.* 2000; 142(5): 1026-1029. doi: 10.1046/j.1365-2133.2000.03491.x
21. Schwartz RA, Burgess GH, Holtermann OA, et al. Mycosis fungoides associated with florid sarcoid reactions. *J Surg Oncol.* 1980; 14(4): 347-357.
22. Kardashian JL, Zackheim HS, Egbert BM. Lymphomatoid papulosis associated with plaque-stage and granulomatous mycosis fungoides. *Arch Dermatol.* 1985; 121(9): 1175-1180.
23. Dabski K, Stoll HL. Granulomatous reactions in mycosis fungoides. *J Surg Oncol.* 1987; 34(4): 217-229. doi: 10.1002/jso.2930340402
24. Argenyi ZB, Goeken JA, Piette WW, Madison KC. Granulomatous mycosis fungoides. Clinicopathologic study of two cases. *Am J Dermatopathol.* 1992; 14(3): 200-210.
25. Flaxman BA, Koumans JA, Ackerman AB. Granulomatous mycosis fungoides. A 14-year follow-up of a case. *Am J Dermatopathol.* 1983; 5(2): 145-151.
26. Papadavid E, Yu RC, Bunker C, et al. Tumour progression in a patient with granulomatous mycosis fungoides. *Br J Dermatol.* 1996; 134(4): 740-743.
27. Sorrells T, Pratt L, Newton J, et al. Spontaneous regression of granulomatous mycosis fungoides in an HIV positive patient. *J Am Acad Dermatol.* 1997; 37(5 Pt 2): 876-880.
28. Telle H, Koeppel MC, Jreissati M, et al. Granulomatous mycosis fungoides. *Eur J Dermatol.* 1998; 8: 506-510.
29. Maillard H, Croué A, François S, et al. Granulomatous mycosis fungoides histologically simulating cutaneous sarcoidosis. *Ann Dermatol Venereol.* 1998; 125(12): 912-915.
30. Wong WR, Yang LJ, Kuo TT, et al. Generalized granuloma annulare associated with granulomatous mycosis fungoides. *Dermatology.* 2000; 200(1): 54-56. doi: 10.1159/000018318
31. Fargnoli MC, Peris K, Francesconi F, et al. Granulomatous mycosis fungoides responsive to gemcitabine. 2002; 12: 479-481.
32. Eisman S, O'Toole EA, Jones A, et al. Granulomatous mycosis fungoides presenting as an acquired ichthyosis. *Clin Exp Dermatol.* 2003; 28(2): 174-176.
33. Von Nida J, Randell P, Heenan P. Granulomatous mycosis fungoides with extensive chest wall involvement. 2004; 45:42-46.
34. Shimauchi T, Kabashima K, Tokura Y. CXCR3 and CCR4 double positive tumor cells in granulomatous mycosis fungoides. *J Am Acad Dermatol.* 2006; 54(6): 1109-1111. doi: 10.1016/j.jaad.2006.02.012
35. Sverzellati N, Poletti V, Chilosi M, et al. The crazy-paving pattern in granulomatous mycosis fungoides: high-resolution computed tomography-pathological correlation. *J Comput Assist Tomogr.* 2006; 30(5): 843-845. doi: 10.1097/01.rct.0000214269.72180.64
36. Hazrati LN, Brill V, Nag S. Muscle and nerve involvement in granulomatous mycosis fungoides. *Muscle Nerve.* 2007; 36(6): 860-865. doi: 10.1002/mus.20818
37. Morihara K, Katoh N, Takenaka H, et al. Granulomatous mycosis fungoides presenting as poikiloderma. *Clin Exp Dermatol.* 2009; 34(6): 718-720. doi: 10.1111/j.1365-2230.2008.03013.x
38. Ishida M, Hotta M, Takikita-Suzuki M, et al. CD8-positive granulomatous mycosis fungoides: a case report with review of the literature. *J Cutan Pathol.* 2010; 37(10): 1072-1076. doi: 10.1111/j.1600-0560.2010.01577.x
39. Gutte R, Kharkar V, Mahajan S, et al. Granulomatous mycosis fungoides with hypohidrosis mimicking lepromatous leprosy. *Indian J Dermatol Venereol Leprol.* 2010; 76(6): 686-690. doi: 10.4103/0378-6323.72470
40. Parker SR, Traywick C, Arbiser JL. Ulcerative granulomatous mycosis fungoides. *Skinmed.* 2010; 8(3): 188-190.
41. Ishida M, Okabe H. Reactive lymphoid follicles with germinal centers in granulomatous mycosis fungoides: a case report with review of the literature. *J Cutan Pathol.* 2013; 40(2): 284-285. doi: 10.1111/cup.12012
42. Iwakura T, Ohashi N, Tsuji N, et al. Calcitriol-induced hypercalcemia in a patient with granulomatous mycosis fungoides and end-stage renal disease. *World J Nephrol.* 2013; 2(2): 44-48. doi: 10.5527/wjn.v2.i2.44
43. Wirtz M, Helbig D. Granulomatous mycosis fungoides: combination therapy with bexarotene and PUVA. *Hautarzt.* 2014; 65(4): 274-276. doi: 10.1007/s00105-014-2784-5
44. Naeini FF, Soghrati M, Abtahi-Naeini B, et al. Co-existence of various clinical and histopathological features of mycosis fungoides in a young female. *Indian J Dermatol.* 2015; 60(2): 214. doi: 10.4103/0019-5154.152588
45. Pousa CM, Nery NS, Mann D, et al. Granulomatous mycosis fungoides: a diagnostic challenge. *An Bras Dermatol.* 2015; 90(4): 554-556. doi: 10.1590/abd1806-4841.20153460